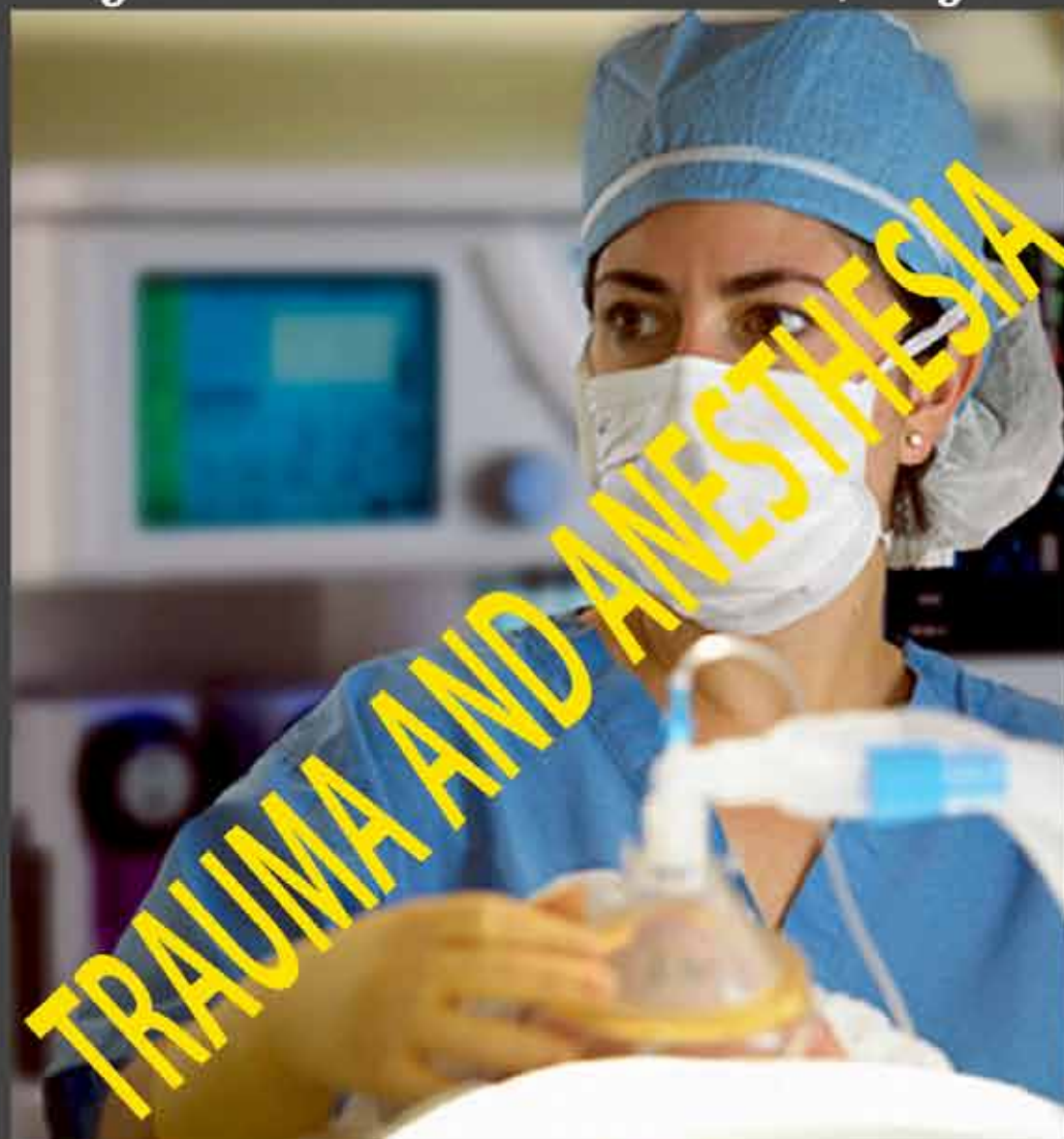

*Ain Shams Journal of Anesthesiology*

**ASJA**

<http://www.asja.eg.net>

[www.journalonweb.com/asja](http://www.journalonweb.com/asja)



ISSN: 1687-7934

ON-LINE ISSN:

2090-925X



Vol. 9/ No. 2

April 2016

# Transversus abdominis plane block versus local anesthetic wound infiltration in patients undergoing open inguinal hernia repair surgery

Ahmed M. Abd El-Hamid, Ehab E. Afifi

Department of Anesthesia and ICU, Faculty of Medicine, Benha University, Benha, Egypt

Correspondence to Ahmed M. Abd El-Hamid, MD, Department of Anesthesia and ICU, Faculty of Medicine, Benha University, 20 Ezz Eldin Omar St., Elharam, Giza, 12111, Egypt  
Tel: +20 100 520 4130;  
e-mail: bashaahmad@yahoo.com

**Received** 14 August 2015

**Accepted** 29 October 2015

**Ain-Shams Journal of Anesthesiology**

2016, 9:280–283

## Objectives

This study aimed to compare the analgesic effect of ultrasound-guided transversus abdominis plane (TAP) block versus wound infiltration in patients undergoing open inguinal hernia repair.

## Patients and methods

A total of 60 male patients scheduled for open unilateral inguinal hernia repair under general anesthesia were randomly allocated into two equal groups: group W received wound infiltration with 0.2 ml/kg of 0.25% levobupivacaine at the site of incision, and group T received ultrasound-guided TAP block with 0.5 ml/kg of 0.25% levobupivacaine. Time to first analgesic request, total morphine requirement over 24 h, and visual analogue pain score at rest and during cough were assessed over the course of 24 h.

## Results

Total morphine requirement during the first 24 h was significantly less in group T. A total of 21 patients in group W required supplemental morphine compared with 13 patients in group T. Time to first analgesic request was significantly longer in group T. Patients receiving TAP block had significantly lower pain scores at rest for 12 h and on cough for 6 h after operation when compared with patients who received wound infiltration.

## Conclusion

TAP block provided more reliable and effective analgesia and less total 24-h postoperative morphine consumption compared with wound infiltration with the local anesthetic.

## Keywords:

local wound infiltration, open inguinal hernia repair, transversus abdominis plane block

Ain-Shams J Anesthesiol 9:280–283

© 2016 Department of Anesthesiology, Intensive Care and Pain Management, Faculty of Medicine, Ain-Shams University, Cairo, Egypt  
1687-7934

## Introduction

Postoperative pain management is of great importance in perioperative anesthetic care [1]. The transversus abdominis plane (TAP) block is a regional anesthesia technique that provides analgesia to the parietal peritoneum as well as the skin and muscles of the anterior abdominal wall [2]. It has been shown to be a safe and effective postoperative adjunct analgesia method in a variety of surgical procedures and it is suggested as part of the multimodal anesthetic approach to enhance recovery after lower abdominal surgeries [3]. Randomized controlled trials have demonstrated the efficacy of TAP block in providing postoperative analgesia for up to 24 h after lower abdominal surgery [4].

Local anesthetic wound infiltration is also a commonly used method for reducing postoperative pain. Postoperative pain relief can be obtained by means of single injection of local anesthesia into the skin and subcutaneous tissue layer at surgical incision sites, which could decrease the pain scores postoperatively [5].

The aim of this study was to compare the analgesic effect of ultrasound-guided TAP block versus wound infiltration in patients undergoing open inguinal hernia repair.

## Patients and methods

This study was conducted in Benha University Hospitals from April 2014 to March 2015. After local ethical committee approval and patient's informed written consent, this prospective randomized comparative clinical trial was conducted on 60 male patients of ASA physical status I and II scheduled for open unilateral inguinal hernia repair under general anesthesia. Patients were allocated randomly using sealed envelopes, according to a

This is an open access article distributed under the terms of the Creative Commons Attribution-NonCommercial-ShareAlike 3.0 License, which allows others to remix, tweak, and build upon the work non-commercially, as long as the author is credited and the new creations are licensed under the identical terms.

computer-generated sequence of random numbers, into two equal groups.

Group W received wound infiltration with 0.2 ml/kg of 0.25% levobupivacaine at the site of incision after induction of general anesthesia and before start of surgical procedure.

Group T received ultrasound-guided TAP block with 0.5 ml/kg of 0.25% levobupivacaine on the same side as the hernia after induction of general anesthesia and before start of surgical procedure.

Exclusion criteria were as follows: inability to consent to the study; skin infection at the puncture site; chest diseases; hepatic, renal, or coagulation disorders; or contraindication to any of the drugs used during the study.

One hour before surgery after insertion of venous access, all patients received premedication in the form of 0.05–0.1 mg/kg of midazolam. Perioperative monitoring included ECG, pulse oximetry, noninvasive arterial blood pressure, capnography, and temperature monitoring. General anesthesia was induced using 1.5–2.5 mg/kg of propofol, 0.5 mg/kg of atracurium to facilitate endotracheal intubation, and 2 µg/kg of fentanyl. Anesthesia was maintained using isoflurane (1 MAC), and atracurium supplements were given every 20 min to maintain muscle relaxation.

TAP block was performed under ultrasound guidance using SonoSite M Turbo (SonoSite, USA) with linear multifrequency 6–13 MHz transducer (L25 × 13–6 MHz linear array) scanning probe. Under complete aseptic condition and with the patient in the supine position, the TAP block was performed laterally behind the midaxillary line between the iliac crest and the subcostal margin. The plane between the internal oblique and transversus abdominis muscle was located around the midaxillary line with the probe transverse to the abdomen. Anteriorly, the needle (Stimuplex D needles; B. Braun, Melsungen, Germany) was passed to come perpendicular to the ultrasound beam and placed between transversus and internal oblique posterior to the midaxillary line. Thereafter, the local anesthetic was injected.

At the end of surgical procedure, anesthesia was discontinued and muscle relaxant reversed using 0.05 mg/kg of neostigmine and 0.02 mg/kg of atropine. Thereafter, patients were extubated and transferred to the postanesthesia care unit. An independent anesthesiologist conducted postoperative assessments and was not aware of group allocation. Rescue analgesia was given with morphine 3 mg intravenous boluses on

demand, or whenever visual analogue scale (VAS) pain score was 4 or greater.

The duration of surgery (the time from skin incision until the removal of surgical drapes), time to first analgesic request (the time from patient's arrival to the postanesthesia care unit until a VAS > 4), total morphine requirement over 24 h, number of patients requiring analgesia, and visual analogue pain score (at rest and during cough) at 2, 4, 8, 12, and 24 h were assessed over the course of 24 h.

### Statistical analysis

- (1) Data were analyzed using SPSS (version 16; SPSS Inc., Chicago, Illinois, USA).
- (2) Quantitative data were presented as a mean and SD and were analyzed using Student's *t*-test.
- (3) Qualitative data were presented as number and percentages and were analyzed using the  $\chi^2$  and *Z* tests.
- (4) Visual analogue score was presented as median and interquartile range and was analyzed using the Mann–Whitney *U*-test.
- (5) A *P*-value less than 0.05 was considered statistically significant, and a *P*-value less than 0.01 was considered statistically highly significant.
- (6) Sample size was calculated according to a pilot study from the first eight patients at  $\alpha$  error 0.05 and 80% power. Assuming 30% decrease in the total morphine consumption, the calculated effect size was 0.709. Thirty patients were required for each group.

### Results

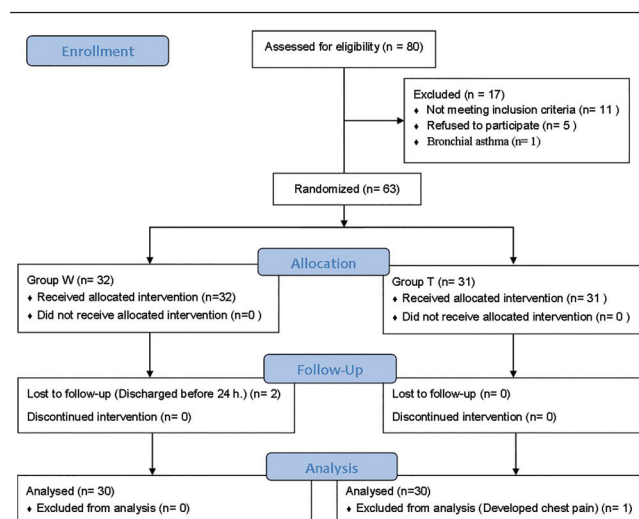
A total of 80 patients were screened during the study period. Of them, 11 patients did not match the inclusion criteria, five patients refused to participate, and one patient was excluded as he had bronchial asthma. A total of 63 patients were included in the study, but three more patients were excluded shortly thereafter because two patients were discharged before 24 h and one patient developed postoperative chest pains. Thus, 60 patients completed the study protocol (Fig. 1).

All patients were similar with respect to patient demographic characteristics, ASA physical status, and duration of surgery (Table 1).

Total morphine requirement during the first 24 h was significantly less in group T compared with group W. A total of 21 patients in group W required supplemental morphine, whereas only 13 patients in group T required supplemental morphine. Time to first analgesic request



Figure 1



Consort flow diagram.

was significantly longer in group T than in group W (Table 1).

Patients receiving TAP block had significantly lower pain scores at rest for 12 h and on cough for 6 h after operation compared with patients who received wound infiltration (Tables 2 and 3).

## Discussion

Postoperative analgesia is one of the main concerns of both the surgeons and the patients. Multiple methods have been put into use to achieve this goal, such as local anesthetic infiltration, epidural analgesia, peripheral nerve block, and patient-controlled analgesia [2].

Several studies have documented that TAP block provided effective postoperative analgesia during the first 24 h following lower abdominal surgical procedures [6–9].

VAS pain score, considered the gold standard of pain quantification, was used to evaluate the severity of postoperative pain at rest and during cough.

The present study found that there was a significantly lower pain score in the TAP group at 12 h postoperatively compared with the wound infiltration group. Total morphine consumption was less in the TAP group. The number of patients who required supplemental morphine was less in TAP block. Time to first analgesic request was longer in the TAP group. This is consistent with the results of Sivapurapu *et al.* [10], who compared the analgesic efficacy of TAP block with that of direct infiltration

Table 1 Demographic characteristics and clinical features

Item	Group W	Group T	P-value
Age (years)	56.32 ± 13.2	52.6 ± 14.8	0.3
Weight (kg)	80.4 ± 19.3	83.1 ± 18.8	0.58
Height (cm)	171.2 ± 30.7	168.3 ± 29.42	0.7
ASA			
I	21 (70)	19 (63.3)	0.58
II	9 (30)	11 (36.7)	
Duration of surgery (min)	55.3 ± 10.41	52.9 ± 9.34	0.35
Total morphine requirement (mg)	8.4 ± 1.2	6.2 ± 1.04	<0.001**
Number of patients requiring analgesia	21 (70)	13 (43.3)	0.03*
Time to first analgesic request (min)	263.1 ± 43.32	489.4 ± 93.2	<0.001**

Data are presented as mean ± SD except ASA and number of patients requiring analgesia, which are presented as n (%);

\*Significant; \*\*Highly significant.

Table 2 Visual analogue scale at rest

Time	Group W		Group T		P-value
	Median	IQR	Median	IQR	
2 h	3	2	2	1	0.027*
4 h	3	2	2	1	0.02*
6 h	3	2	2	2	0.015*
12 h	4	1	3	1	0.011*
24 h	4	2	4	2	0.47

IQR, interquartile range; \*Significant.

Table 3 Visual analogue scale during cough

Time	Group W		Group T		P-value
	Median	IQR	Median	IQR	
2 h	4	2	3	1	0.027*
4 h	4	2	3	1	0.02*
6 h	4	2	3	2	0.022*
12 h	5	2	4	2	0.28
24 h	5	2	5	2	0.065

IQR, interquartile range; \*Significant.

of local anesthetic into surgical incision in lower abdominal gynecological procedures under general anesthesia. Time to rescue analgesic was significantly longer and the VAS scores were lower in the TAP group. The 24 h morphine requirement and the incidence of side effects were less in the TAP group. In a meta-analysis conducted by Mishriky *et al.* [11], they reported that TAP block significantly reduced opioid consumption and reduced pain scores for up to 12 h postoperatively.

In a prospective, randomized, double-blind study of 64 patients undergoing inguinal hernia repair, Salman *et al.* [12] found that TAP block provided effective

analgesia, reducing total 24-h postoperative analgesic consumption and morphine requirement.

## Conclusion

We conclude that ultrasound-guided TAP block provided more reliable and effective analgesia and lower total 24-h postoperative morphine consumption compared with local anesthetic wound infiltration.

## Financial support and sponsorship

Nil.

## Conflicts of interest

There are no conflicts of interest.

## References

- Schug SA. 2011 — the global year against acute pain. *Anaesth Intensive Care* 2011; 39:11–14.
- Yu N, Long X, Lujan-Hernandez JR, Succar J, Xin X, Wang X. Transversus abdominis-plane block versus local anesthetic wound infiltration in lower abdominal surgery: a systematic review and meta-analysis of randomized controlled trials. *BMC Anesthesiol* 2014; 14:121.
- Young MJ, Gorlin AW, Modest VE, Quraishi SA. Clinical implications of the transversus abdominis plane block in adults. *Anesthesiol Res Pract* 2012; 2012: 731645.
- Al-Sadek WM, Rizk SN, Selim MA. Ultrasound guided transversus abdominis plane block in pediatric patients undergoing laparoscopic surgery. *Egypt J Anaesthesia* 2014; 30:273–278.
- Coughlin SM, Karanicolas PJ, Emmerton-Coughlin HM, Kanbur B, Kanbur S, Colquhoun PH. Better late than never? Impact of local analgesia timing on postoperative pain in laparoscopic surgery: a systematic review and meta-analysis. *Surg Endosc* 2010; 24:3167–3176.
- McDonnell JG, O'Donnell B, Curley G, Heffernan A, Power C, Laffey JG. The analgesic efficacy of transversus abdominis plane block after abdominal surgery: a prospective randomized controlled trial. *Anesth Analg* 2007; 104:193–197.
- McDonnell JG, O'Donnell BD, Farrell T, Gough N, Tuite D, Power C, Laffey JG. Transversus abdominis plane block: a cadaveric and radiological evaluation. *Reg Anesth Pain Med* 2007; 32:399–404.
- El-Dawlatly AA, Turkistani A, Kettner SC, Machata AM, Delvi MB, Thallaj A, *et al.* Ultrasound-guided transversus abdominis plane block: description of a new technique and comparison with conventional systemic analgesia during laparoscopic cholecystectomy. *Br J Anaesth* 2009; 102:763–767.
- Bouhassira D, Attal N, Alchaar H, Boureau F, Brochet B, Bruxelle J, *et al.* Comparison of pain syndromes associated with nervous or somatic lesions and development of a new neuropathic pain diagnostic questionnaire (DN4). *Pain* 2005; 114:29–36.
- Sivapurapu V, Vasudevan A, Gupta S, Badhe AS. Comparison of analgesic efficacy of transversus abdominis plane block with direct infiltration of local anesthetic into surgical incision in lower abdominal gynecological surgeries. *J Anaesthesiol Clin Pharmacol*. 2013; 29:71–75.
- Mishriky BM, George RB, Habib AS. Transversus abdominis plane block for analgesia after cesarean delivery: a systematic review and meta-analysis. *Can J Anaesth* 2012; 59:766–778.
- Salman AE, Yetişir F, Yürekli B, Aksoy M, Yildirim M, Kiliç M. The efficacy of the semi-blind approach of transversus abdominis plane block on postoperative analgesia in patients undergoing inguinal hernia repair: a prospective randomized double-blind study. *Local Reg Anesth* 2013; 6:1–7.